



PATIENT

Bernard Carnahan

PRESENTING CLINICAL SIGNS

History: History of hyperadrenocorticism and has been on Trilostane. Recent collapse episode. Arrhythmia heard on exam.

SPECIES

Canine

ELECTROCARDIOGRAPHIC FINDINGS *Note: Single lead ECGs are evaluated as a rhythm strip. Morphology/MEA cannot be definitively commented on.

A single lead ECG is available; 25mm/s, 20mm/mV. The underlying rhythm is sinus in origin, with an average heart rate of 110bpm (range 83-136bpm). The P and QRS morphologies are positive. Isolated VPCs throughout; singles only with a brief period of bigeminy. No couplets, triplets or VT appreciated. No supraventricular ectopic beats, pauses or other dysrhythmias observed. ECG diagnosis: Normal sinus rhythm isolated VPCs; brief bigeminy.

BREED

American Bulldog

SEX

Male Neutered

ECHOCARDIOGRAM FINDINGS

2D, m-mode, color flow and doppler imaging is available. Moderate left ventricular dilation with depressed myocardial function (LVIDdN: 1.94, LVIDsN: 1.46). Normal LV wall thickness with mildly increased sphericity. Mild to moderate left atrial enlargement. The mitral valve appears normal with no prolapse into the left atrial lumen. Trace mitral regurgitation. Trace tricuspid regurgitation. Mild right atrial and ventricular dilation. The aortic valve is normal in morphology and mobility. No subvalvular ridge present; normal LVOT velocity. No aortic insufficiency. Normal pulmonic valve with no pulmonic insufficiency seen. Normal PA outflow velocities. No pericardial or pleural effusion noted. No obvious cardiac tumors. Irregular rate and rhythm throughout.

AGE

8 years

WEIGHT

63lbs

CARDIAC CHART

INTERPRETED BY

Maggie Machen Lamy,
DVM, DACVIM
(Cardiology)

CANINE CARDIAC PARAMETERS	MR VMAX (m/s)	TR VMAX (m/s)	LA/AO (Boon method)	LA/AO (Heart Base; Swe)	FS (%)	EF (%)	EPSS (cm)
NORMAL PARAMETER	4.5-5.5	<2.7	1.3	<1.6	28-40	40-100	<0.6
PATIENT	NA	NM	1.5	1.5	19	25	1.3
CANINE CARDIAC PARAMETERS	HR (BPM)	AV VMAX (m/s)	PV MAX (m/s)	BODY WEIGHT (kg)	LA 2D short axis Base view (cm)	LVIDd Avg; 2D and m-mode short axis (cm)	LVIDs Avg; 2D and m-mode short axis (cm)
NORMAL PARAMETER	50-100	0.7-1.7	0.7-1.6	BELOW	BELOW	BELOW	BELOW
PATIENT	NM	1.3	0.8	28.6	3.3	5.2	4.2
*Normal chamber parameters expressed as a mean value (SD)				3	1.27 (5.3)	2.46 (2.46)	1.36 (5.5)
BODY WEIGHT DEPENDENT PARAMETERS				5	1.40 (4.5)	2.74 (5.2)	1.60 (4.7)
<i>*Note: All measurements based upon multi-modal images and methods. An average value is reported.</i>				10	1.50 (3.8)	3.27 (3.5)	2.06 (3.1)
				15	1.83 (2.0)	3.71 (2.4)	2.43 (2.1)
				20	2.02 (1.9)	4.14 (2.2)	2.80 (2.0)
				25	2.18 (2.4)	4.48 (2.9)	3.10 (2.5)
				30	2.33 (3.3)	4.83 (3.9)	3.39 (3.4)
				35	2.48 (4.3)	5.17 (5.0)	3.69 (4.5)
				40	2.62 (5.2)	5.48 (6.1)	3.96 (5.4)
				50	2.88 (7.1)	6.07 (8.3)	4.46 (7.4)

Adapted from June Boon, Veterinary Echocardiography, 1998
Rishniw M and Hollis NE, J Vet Intern Med 2000; 14:429-435
Hansson et al, Vet Rad and Ultrasound 2002
Bonagura et al. Echocardiography: principles of interpretation, Vet Clin North Am 15:1177, 1995

IMAGING PERFORMED BY

Kelly Romero

HOSPITAL NAME

Mulnix Animal Clinic

REFERRING VET

Dr. Gaffney

INVOICE

24805

DATE

6/15/22



PATIENT	<u>INTERPRETATION OF THE FINDINGS & FURTHER RECOMMENDATIONS</u>
Bernard Carnahan	Unfortunately, this patient has changes most consistent with occult Dilated Cardiomyopathy (DCM). There is a decline in systolic function, accompanied by LV dilation and increased sphericity. The right heart is also affected with RA and RV enlargement. Finally, the LA is mild to moderately dilated, indicating relatively low risk for imminent complication; however, risk for progression to clinical signs is elevated in the future. Going forward there will be risk for development of right or left sided congestive heart failure, malignant arrhythmias (AF, VT), collapse and/or sudden death.
SPECIES	
Canine	
BREED	
American Bulldog	Systolic failure can be primary in nature (DCM/ARVC) or secondary to taurine deficiency, certain drugs such as Doxorubicin, myocarditis, hypothyroidism, tachycardia-induced cardiomyopathy, or infiltrative disease such as lymphoma. In a Bulldog, primary disease is certainly possible. That being said, consider testing for primary causes that may be treatable such as a full thyroid panel. A cTnI level can be submitted to further investigate possible infiltrative/inflammatory damage (myocarditis; not suspected). Finally, a taurine level may be helpful (to screen for concurrent malabsorption issue). Regardless of result, I would institute a taurine supplement to cover all bases. A thorough diet history is recommended. Although a non-grain free diet is noted, a nontraditional diet should also be avoided. Regardless of cause, prognosis is guarded long term with risk for complications going forward.
SEX	
Male Neutered	
AGE	
8 years	
WEIGHT	
63lbs	Based upon these findings, recommend Pimobendan as below. Additionally, a baseline BP is recommended with institution of an ACEI if >150mmHg. Monitor for development of a cough, labored breathing, exercise intolerance or collapse episodes in the future. Monitoring of sleeping breathing rates at home is recommended to screen for progression in the future. Mild activity restriction is advised. Omega fatty acid supplementation and mild salt restriction may be of some long-term benefit.
INTERPRETED BY	
Maggie Machen Lamy, DVM, DACVIM (Cardiology)	The ECG also shows abnormalities, with isolated VPCs. These have likely developed secondary to structural disease in this case. VPCs are generated from abnormal conductive or fibrotic tissue in the heart, and even frequent single VPCs will often cause no clinical signs in dogs. When sustained however, ventricular tachycardia can lead to symptoms such as lethargy and collapse. Unfortunately there is always an elevated risk for collapse and sudden death in any arrhythmic patient, and even on medications this risk unfortunately still persists.
IMAGING PERFORMED BY	
Kelly Romero	
HOSPITAL NAME	
Mulnix Animal Clinic	While typically single VPCs do not warrant therapy, this must be interpreted in light of the clinical signs and echo findings. In a patient with a collapse episode and underlying DCM, there is great concern for development of malignant arrhythmias as the cause. A holter monitor can and should be considered to know the full extent of the arrhythmia outside of a stressful environment as the gold standard next step. If this is declined or not possible, I would err on the side of caution in this case and institute sotalol, given the exceedingly high risk for life threatening arrhythmias going forward. Discussion with the owner is advised.
REFERRING VET	
Dr. Gaffney	
INVOICE	
24805	Once the arrhythmia is further assessed and Pimobendan is on board, anesthetic risk remains moderately elevated if needed. Cardiac protective drug choices (opioid/benzodiazepine premedication, propofol or alfaxalone induction, isoflurane gas) are recommended. Avoid ketamine, telazol, dexdomitor (or other alpha-2 agonists) and acepromazine. Pre-oxygenate for 5-10 minutes prior to induction. Monitor for arrhythmias, hypotension, and hypoxia both intra and post-operatively and intervene as necessary Recommend having lidocaine CRI available for use in the event of worsening ventricular arrhythmias under anesthesia (CRI 50–75mcg/kg/min).
DATE	
6/15/22	



PATIENT

Bernard Carnahan

SPECIES

Canine

BREED

American Bulldog

SEX

Male Neutered

AGE

8 years

WEIGHT

63lbs

INTERPRETED BY

Maggie Machen Lamy,
DVM, DACVIM
(Cardiology)

IMAGING PERFORMED BY

Kelly Romero

HOSPITAL NAME

Mulnix Animal Clinic

REFERRING VET

Dr. Gaffney

INVOICE

24805

DATE

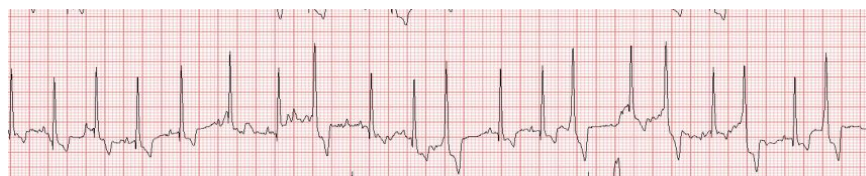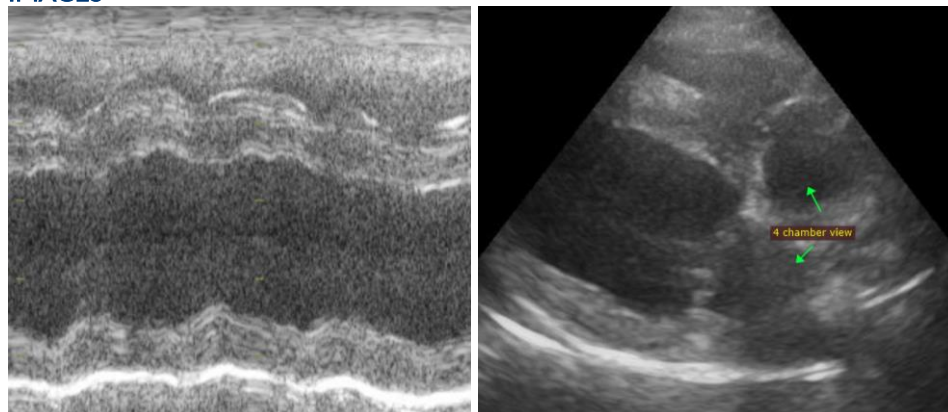
6/15/22

PLAN

Institute Pimobendan 0.25-0.3mg/kg PO q12h. Baseline BP recommended. If >150mmHg, institute ACEI 0.5mg/kg PO q12h. Institute taurine supplement 1000mg PO q12h. Consider thyroid panel, cTnI, taurine level as discussed. A thorough diet history with avoidance of BEG options is recommended. Consider a holter monitor as discussed. If declined, recommend Sotalol 1-2mg/kg (available in 80 or 120mg tabs) PO q12h. Recheck ECG or ideally holter in 2 weeks to assess response. If any worsening in clinical signs on the medication, immediate reassessment of the ECG is recommended.

A recheck echocardiogram is recommended in 6 months to assess for progression, sooner if clinical signs arise.

IMAGES



Ventricular bigeminy

The information and recommendations provided are based on the images presented by the referring veterinarian. No evaluation can be communicated regarding pathology that was not visible in the image/video clips provided.

Thank you for this referral. This report was generated using transcription software, and minor dictation errors may be present. If the clinical or image interpretation does not parallel your findings or if I can be of any further assistance, please contact me.

Maggie Machen Lamy, DVM
Diplomate of the American College of Veterinary Internal Medicine (Cardiology)
info@sonopath.com